

STATE-OF-THE-ART REVIEW

Multimodality Imaging in the Diagnostic Work-Up of Patients With Cardiac Masses

JACC: CardioOncology State-of-the-Art Review

Francesco Angeli, MD,^{a,b,*} Francesca Bodega, MD,^{a,b,*} Luca Bergamaschi, MD,^{a,b} Matteo Armillotta, MD,^{a,b} Sara Amicone, MD,^{a,b} Lisa Canton, MD,^{a,b} Damiano Fedele, MD,^{a,b} Nicole Suma, MD,^{a,b} Daniele Cavallo, MD,^{a,b} Alberto Foà, MD, PhD,^{a,b} Marta Belmonte, MD,^{c,d} Vincenzo Russo, MD,^e Domenico Attinà, MD,^e Fabio Niro, MD,^e Rachele Bonfiglioli, MD,^f Stefano Fanti, MD,^f Anna Giulia Pavon, MD,^g Marco Guglielmo, MD,^{h,i} Saima Mushtaq, MD,^j Maria Abbondanza Pantaleo, MD,^{b,k} Daniele Andreini, MD,^{l,m} Luigi Lovato, MD,^e Gianluca Pontone, MD,^{j,n} Juan Lopez-Mattei, MD,^o Pasquale Paolisso, MD, PhD,^{l,m,†} Carmine Pizzi, MD^{a,b,†}

ABSTRACT

Cardiac masses encompass a diverse range of benign and malignant tumors as well as pseudotumors. Accurate histologic identification is essential for guiding appropriate treatment, yet the diagnostic process remains challenging. Although biopsy is traditionally the diagnostic gold standard, its invasive nature and associated risks limit its application. A noninvasive multimodality imaging approach has recently emerged as an alternative, but standardized protocols and supporting evidence are still lacking. Echocardiography is typically the initial imaging modality, with cardiac magnetic resonance recognized as the noninvasive diagnostic gold standard. Cardiac computed tomography provides complementary data to aid in diagnosis and management, while positron emission tomography serves as a third-level imaging option. This state-of-the-art review highlights the role of current multimodality imaging techniques in diagnosing and managing cardiac masses and explores future directions for their applications. (JACC CardioOncol. 2024;■:■-■)

© 2024 The Authors. Published by Elsevier on behalf of the American College of Cardiology Foundation. This is an open access article under the CC BY-NC-ND license (<http://creativecommons.org/licenses/by-nc-nd/4.0/>).

From the ^aCardiology Unit, IRCCS Azienda Ospedaliera-Universitaria di Bologna, Bologna, Italy; ^bDepartment of Medical and Surgical Sciences, DIMEC, Alma Mater Studiorum, University of Bologna, Bologna, Italy; ^cDepartment of Advanced Biomedical Sciences, University of Naples, Federico II, Naples, Italy; ^dCardiovascular Center Aalst, OLV Hospital, Aalst, Belgium; ^eDepartment of Pediatric and Adult Cardio-Thoracovascular, Oncohematologic and Emergencies Radiology Unit, IRCCS Azienda Ospedaliero-Universitaria di Bologna, Bologna, Italy; ^fInstitute of Nuclear Medicine, Department of Experimental, Diagnostic and Specialty Medicine, University of Bologna, Policlinico S. Orsola-Malpighi, Bologna, Italy; ^gDivision of Cardiology, Cardiocentro Ticino Institute, Ente Ospedaliero Cantonale, Lugano, Switzerland; ^hDepartment of Cardiology, Division of Heart and Lungs, Utrecht University, Utrecht University Medical Center, Utrecht, the Netherlands; ⁱDepartment of Cardiology, Haga Teaching Hospital, the Hague, the Netherlands; ^jDepartment of Perioperative Cardiology and Cardiovascular Imaging, Centro Cardiologico Monzino IRCCS, Milan, Italy; ^kOncology Unit, IRCCS Azienda Ospedaliero-Universitaria di Bologna, Bologna, Italy; ^lClinical Cardiology and Cardiovascular Imaging Unit, Galeazzi-Sant'Ambrogio Hospital, IRCCS, Milan, Italy; ^mDepartment of Biomedical and Clinical Sciences, University of Milan, Milan, Italy; ⁿDepartment of Biomedical, Surgical and Dental Sciences, University of Milan, Milan, Italy; and the ^oLee Health Heart Institute, Fort Myers, Florida, USA. *Drs Angeli and Bodega contributed equally to this work. †Drs Paolisso and Pizzi contributed equally to this work.

The authors attest they are in compliance with human studies committees and animal welfare regulations of the authors' institutions and Food and Drug Administration guidelines, including patient consent where appropriate. For more information, visit the [Author Center](#).

Manuscript received May 9, 2024; revised manuscript received September 5, 2024, accepted September 9, 2024.

**ABBREVIATIONS
AND ACRONYMS****¹⁸F-FDG** = ¹⁸F-fluorodeoxyglucose**AUC** = area under the curve**CAP** = chest, abdominal, and pelvic**CMR** = cardiac magnetic resonance**CT** = computed tomography**LGE** = late gadolinium enhancement**LV** = left ventricle/ventricular**PCT** = primary cardiac tumor**PET** = positron emission tomography**RT3DE** = real-time 3-dimensional echocardiography**SUVmax** = maximum standardized uptake value**TEE** = transesophageal echocardiography

Cardiac masses present a complex clinical scenario, encompassing benign tumors, malignant tumors (both primary and secondary), and tumorlike masses, also known as pseudotumors.^{1,2} Approximately 75% to 90% of primary cardiac tumors (PCTs) are benign, with myxomas being the predominant histotype in adults, while nonmyxoma histotypes are more common in children and adolescents.³ Overall, benign tumors are usually associated with favorable long-term prognosis.⁴ Among malignant PCTs, sarcomas are the most common (65%-88%), followed by lymphomas (27%) and mesotheliomas (8%).³ The prognosis for patients with malignant tumors is generally poor, with survival rates of 45.3% at 1 year and only 11.5% at 5 years.^{4,5} Pseudotumors include cardiac masses that do not arise from neoplastic processes, such as thrombi, cysts, lipomatosis, valvular nodules, and Lambli's excrescences, as well as anatomical variants. These are relatively common and often misdiagnosed.^{1,6,7}

Over the past decade, the prevalence of cardiac masses has increased because of technical advances in noninvasive imaging technology and its wider application.^{8,9} This has encouraged the adoption of a multimodality imaging approach in the evaluation of the complex and heterogeneous nature of cardiac masses. However, despite proposed diagnostic algorithms, there are currently no established guidelines for structuring the multimodality imaging approach to cardiac masses.⁹⁻¹² As a result, physicians treating patients with cardiac masses in various settings may struggle to integrate different imaging modalities, often relying on personal experience and local expertise. The absence of a standardized approach has 2 major implications: at smaller, peripheral centers, physicians may need to refer patients with cardiac masses to tertiary centers for a more comprehensive noninvasive imaging evaluation. In contrast, at centers with access to all imaging techniques, physicians may prescribe unnecessary and expensive examinations that provide no additional benefit to patients, potentially causing harm by delaying treatment. This practice is also unsustainable for hospitals because of the associated costs.^{12,13}

This review expands on the role of multimodality imaging in current clinical practice, building on previous documents,^{9,12} by: 1) examining the strengths and feasibility of each imaging modality to guide

HIGHLIGHTS

- Multimodality imaging is key for the diagnostic work-up of cardiac masses.
- Multimodality imaging effectively detects red flags for malignancy in cardiac tumors.
- This approach reduces diagnostic delays and optimizes resources, improving outcomes.









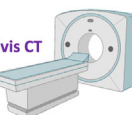


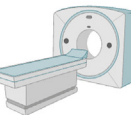

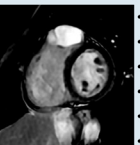
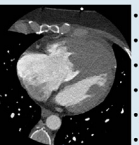
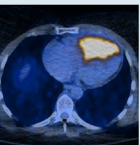
physicians in their optimal use and selection; 2) presenting the latest evidence on diagnostic accuracy for detecting cardiac mass malignancy and etiology across different techniques; 3) describing the latest advances in the field and the potential applications of emerging tools; and 4) promoting a globally standardized approach for implementation in both clinical practice and research, with the ultimate goal of stimulating research in the field and collecting homogeneous data from heterogeneous patient populations.

**MULTIMODALITY DETECTION OF
CARDIAC MASS MALIGNANCY**

The new era of multimodality imaging offers the potential to improve the diagnosis, management, and potentially outcomes of patients with cardiac masses in a cost-effective manner. An overview of the noninvasive imaging techniques is provided in [Figure 1](#). Remarkably, awareness of the “red flags” of malignancy, along with an understanding of the strengths and limitations of each imaging modality, enables high diagnostic accuracy. This approach increases the likelihood of a definite diagnosis at each step, while optimizing the use of resources. Case examples highlighting key cardiac mass features for each imaging modality are presented in [Supplemental Figures 1 to 4](#).

[Table 1](#) outlines the usefulness of each imaging technique in achieving a definite diagnosis for the most common cardiac masses. Although the performance of each imaging modality may vary on the basis of cardiac mass histotype, integrating these techniques in a multimodality approach allows the accurate detection of malignancy and, in some cases, identification of the cardiac mass histotype in a noninvasive setting. The characteristics of the most common cardiac masses on multimodality imaging are shown in [Table 2](#).

FIGURE 1 Overview of Imaging Modalities in the Diagnostic Work-Up of Cardiac Masses

Echocardiography	Cardiac Magnetic Resonance	Computed Tomography	Positron Emission Tomography
 <p>TTE is usually the initial imaging modality*</p> <p>TEE should be considered in case of small and mobile CMs</p>  	 <p>CMR represents the gold-standard</p>  	 <p>Cardiac CT</p> <ul style="list-style-type: none"> - Pre-surgical planning - Exclude CAD - CMR contraindicated or not available <p>Chest-abdomen-pelvis CT</p> <ul style="list-style-type: none"> - Detection of primary extra-cardiac tumor - Staging of malignancy  	 <p>¹⁸F-FDG PET/CT</p> <ul style="list-style-type: none"> - Staging of malignancy - Non-conclusive CMR and/or CCT  
<p>What to look for?</p>  <ul style="list-style-type: none"> • Localization • Anatomical variants • Size and Morphology • Invasion • Pericardial effusion • Hemodynamic impact 	<p>What to look for?</p>  <ul style="list-style-type: none"> • Localization • Anatomical variants • Size and Morphology • Invasion • Pericardial effusion • Tissue characterization 	<p>What to look for?</p>  <ul style="list-style-type: none"> • Localization • Size and morphology • Margins and invasion • Density signal • Calcifications • Contrast enhancement 	<p>What to look for?</p>  <ul style="list-style-type: none"> • CM SUV max • CM TLG • CM MTV • Systemic localizations (metastases)
<p>Pros ✓</p> <ul style="list-style-type: none"> • Large-scale availability • Low-cost • Repeatability <p>Cons ✗</p> <ul style="list-style-type: none"> • Limited tissue characterization • Limited accuracy in case of poor acoustic window 	<p>Pros ✓</p> <ul style="list-style-type: none"> • Tissue characterization • Higher spatial resolution <p>Cons ✗</p> <ul style="list-style-type: none"> • Need for Local availability and operator expertise • Long acquisition protocols 	<p>Pros ✓</p> <ul style="list-style-type: none"> • Widely accessible • Malignancy staging <p>Cons ✗</p> <ul style="list-style-type: none"> • Presence of artifacts due to device or ↑HR • No info on the hemodynamic impact 	<p>Pros ✓</p> <ul style="list-style-type: none"> • Helpful in case of CMR/CCT non-conclusive • Malignancy staging <p>Cons ✗</p> <ul style="list-style-type: none"> • Adequate patients' preparation* • Limited availability
<p>Tips and tricks ⓘ</p> <ul style="list-style-type: none"> • CM dimensions might not be related to histology. • Recognize normal anatomical variants. • LV dimension/function may suggest an apical thrombus. • Contrast-enhanced echo aids to distinguish vascular tumors from thrombi. • DEM score ≥ 5 is suggestive of malignancy. 	<p>Tips and tricks ⓘ</p> <ul style="list-style-type: none"> • Customized acquisitions based on mass location. • T1/T2 mapping may provide further information. • Melanoma metastasis has ↓ T1 (Melanin-rich tumors). • CMR Mass Score ≥5 is suggestive of malignancy. 	<p>Tips and tricks ⓘ</p> <ul style="list-style-type: none"> • EKG gating is recommended. • Calcifications might suggest pseudo-tumors. • Find the primitive malignant tumor. • Preferable in case of great vessel involvement (i.e. pulmonary artery sarcoma). 	<p>Tips and tricks ⓘ</p> <ul style="list-style-type: none"> • >12 h of fasting with a fatty meal without carbohydrates is needed. • Poor specificity in case of benign tumors with high metabolic activity. • Possibility of CT/CMR fusion imaging. • SUV max ≥4.9 - TLG ≥29 - MTV ≥8.2 are suggestive of malignancy.

The strengths and weaknesses of each imaging modality in diagnosing cardiac masses are outlined. *Transthoracic echocardiography (TTE) may not be necessary for all patients if a cardiac mass is already found on cardiac magnetic resonance (CMR) or computed tomography (CT). ¹⁸F-FDG = ¹⁸F-fluorodeoxyglucose; CAD = coronary artery disease; CCT = cardiac computed tomography; CM = cardiac mass; DEM = diagnostic echocardiographic mass; EKG = electrocardiographic; HR = heart rate; LV = left ventricular; MTV = metabolic tumor volume; PET = positron emission tomography; pts = patients; SUVmax = maximum standardized uptake value; TEE = transesophageal echocardiography; TLG = total lesion glycolysis.

ECHOCARDIOGRAPHY

FOR WHOM AND WHEN. Echocardiography is the initial imaging approach for patients with suspected cardiac masses. In cases in which there is uncertainty about the localization of a mass or when better visualization of small, mobile masses is needed, transesophageal echocardiography (TEE) may be performed.⁹ Additionally, contrast-enhanced echocardiography can help in differentiating vascular tumors from thrombi.¹⁴

STRENGTHS AND WEAKNESSES. Echocardiography offers several advantages: it is widely available, can be performed at any time, is low cost, and does not require ionizing radiation. It also plays an important role in the follow-up of patients with cardiac masses.^{9,15,16} In addition, it provides valuable

information about overall cardiac morphology and function. However, its effectiveness can be limited by poor acoustic windows, and it may struggle to assess the right chambers, pericardium, or great vessels, with ultrasound artifacts sometimes proving misleading.⁹ Last, echocardiography allows only limited tissue characterization and has constraints in evaluating cardiac mass infiltration.

WHAT TO LOOK FOR. When using echocardiography to assess cardiac masses, there are several key features that can help differentiate between benign and malignant masses.

The first and most relevant aspect in differentiating between benign and malignant masses is their localization. Benign masses are typically located in the left heart chambers, whereas malignancies are more often found on the right side, in the

TABLE 1 Usefulness of Each Tool in the Multimodality Approach to Cardiac Masses

	TTE/TEE	CMR	CCT	PET	Biopsy
Benign tumors					
Myxoma					
Typical ^a	+++	+++	++	+/-	-
Atypical ^b	++	+++	++	+	+/-
Fibroelastoma	+++	+/-	+	+/-	-
Lipoma	+	+++	++	+/-	-
Pseudotumors					
Anatomical variants	+++	+++	+++	+/-	-
Thrombus	++	+++	++	+/-	-
Cyst	+	+++	+++	++	-
Vegetations	+++	+/-	+	++	-
Malignant tumors					
Primary malignant	++	+++	++	++	+++
Metastasis	+	+++	+++	+++	+++

^aTypical myxoma: a mass with regular margins, adhering to the left side of the interatrial septum at the fossa ovalis level. ^bAtypical myxoma: Any morphology or location different from that of a typical myxoma.

CCT = cardiac computed tomography; CMR = cardiac magnetic resonance; PET = positron emission tomography; TEE = transesophageal echocardiography; TTE = transthoracic echocardiography; +++ = gold standard; ++ = valuable additional information; + = suboptimal diagnostic performance; +/- = usually not indicated; - = not indicated.

pericardium, or in the pulmonary arteries (Supplemental Figures 1A and 1B).^{6,7} Specifically, some cardiac masses have “typical” localizations: atrial myxomas have a pedunculated implantation on the left side of the interatrial septum, thrombi are usually located in the left ventricular (LV) apex, and fibroelastomas typically arise on the valvular apparatus.

It is also important to differentiate true cardiac masses from anatomical variants, such as the Chiari network, Eustachian valve, crista terminalis (right atrium), Coumadin ridge (left atrium), false chordae, and trabeculae (LV), which are often mistaken for cardiac masses. These variants do not require further diagnostic investigation or treatment. Recognizing these structures and their locations using high-quality echocardiography can prevent unnecessary second-level imaging tests.

Another key feature that can help differentiate between benign and malignant cardiac masses is their size and morphology. Benign masses are often pedunculated, mobile, with regular margins (ie, >50% of the border clearly demarcated), and tend to adhere to the interatrial septum or heart valves. Conversely, malignant masses are generally larger, with irregular margins, inhomogeneous appearance, sessile implantation, and a polylobate shape (Supplemental Figures 1C and 1D). However, benign masses, such as myxomas, can also grow to substantial sizes while remaining asymptomatic for extended periods.

Invasion of surrounding structures is another critical feature that can help distinguish malignant cardiac masses. Although difficult to assess, the presence of invasion of neighboring structures strongly suggests malignancy. This may be indicated by disruption of surrounding tissues and extension of the mass across the pericardium and into the myocardium, with interruption of the epicardial and endocardial contours. Echocardiographic signs include evidence of differing acoustic properties compared with normal myocardium, as infiltrative tissue typically displays a distinct speckle pattern with harmonic imaging, increased thickness in adjacent myocardial segments, and hypokinesia or akinesia in a focal myocardial area that does not follow a coronary distribution pattern, ruling out ischemic causes (Supplemental Figures 1E and 1F).¹⁷

The presence and severity of pericardial effusion can also help distinguish between benign and malignant cardiac masses. Malignant masses are more frequently associated with significant (moderate to severe) pericardial effusion (Supplemental Figure 1F). In contrast, pericardial effusion in benign cardiac masses, if present, is typically mild, particularly in cases of pericardial localization.

The hemodynamic impact of cardiac masses is another important feature to consider. Valvular impingement or obstruction of ventricular inflow and outflow tracts, commonly seen with benign masses, may necessitate urgent surgical treatment. Additionally, cardiac tamponade can occur in the presence of pericardial effusion, predominantly in cases involving malignant masses (Supplemental Figures 1G and 1H).⁹

Echocardiography has been shown to accurately differentiate between malignant and benign cardiac masses and to identify specific etiologies of benign cardiac tumors. For example, cardiac myxomas are typically left-sided masses that adhere to the interatrial septum by a stalk.¹⁸ Conversely, papillary fibroelastomas are small, highly mobile, pedunculated masses that usually adhere to the aortic or mitral valves. Unlike vegetations, fibroelastomas are commonly detected on the LV side of the mitral valve and the aortic side of the aortic valve without causing significant valvular dysfunction.⁹

LATEST ADVANCES. Echocardiography can now be enhanced with real-time 3-dimensional techniques (real-time 3-dimensional echocardiography [RT3DE]), a volumetric approach that captures the entire cardiac mass, providing an accurate evaluation of its volume, attachments, and relationships with surrounding structures (Figures 2A and 2B).¹⁹ Besides diagnosis, RT3DE may also be useful for

TABLE 2 Features of the Most Common Cardiac Masses at Multimodality Imaging

	TTE/TEE	CMR		CCT	PET
		Precontrast Tissue Characterization	Postcontrast Tissue Characterization		
Benign tumors					
Myxoma	Mobile, attached by a stalk, most frequently at the fossa ovalis Heterogeneous enhancement after contrast	T1: isointense T2: hyperintense	Perfusion: diffuse and mild LGE: heterogeneous	Regular margins Calcification usually present No or mild uptake of contrast	No/mild uptake
Fibroelastoma	Mobile, small size, usually located at heart valves No enhancement after contrast	T1: isointense T2: isointense	Perfusion usually not assessable LGE: homogeneous or absent	Focal low attenuation on a valve surface No contrast uptake	No uptake
Lipoma	Broad based, immobile, without a pedicle, and well circumscribed Hyperechoic if intracavitary, hypoechoic in the pericardial space No/mild enhancement after contrast	India ink artifact T1: hyperintense T2: hyperintense T1-w fat-sat: dark	Perfusion: absent LGE: absent	Homogeneous Low attenuation No contrast uptake	No/mild uptake
Pseudotumors					
Thrombus	Hyperechoic lesion Located on akinetic segments of the myocardium; LAA; indwelling catheters No enhancement after contrast	T1: Hypointense (hyperintense if recent) T2: hypointense (hyperintense if recent)	Perfusion: absent EGE: no enhancement LGE: absent	Filling defect on initial and delayed acquisition No contrast uptake	No uptake
Cyst	Unilocular, anechoic with well-defined and regular margins No communication with the cardiac cavities No enhancement after contrast	T1: hypointense T2: hyperintense	Perfusion: absent LGE: absent	Thin walled, with/without septation No contrast uptake	No uptake
Malignant Tumors					
Angiosarcoma	Nodular or polylobate with irregular mass (usually in the right atrium) Common invasion of adjacent structures ("sheetlike" thickening if pericardial invasion) Pericardial effusion or direct pericardial infiltration Intense enhancement after contrast	T1: isointense/hyperintense T2: hyperintense	Perfusion: diffuse/heterogenous with multiple nodular areas of high intensity ("cauliflower" appearance) LGE: heterogeneous	Hemorrhagic, necrotic areas without enhancement Heterogeneous uptake of contrast	High uptake
Primary cardiac lymphoma	Homogeneous, infiltrating mass; nodular appearance intruding into the heart chambers Usually associated with pericardial effusion Intense enhancement after contrast	T1: isointense/hypointense T2: mildly hyperintense	Perfusion: heterogeneous/mild LGE: heterogeneous	Diffuse infiltration of soft tissue Multiple nodule Heterogeneous contrast uptake	High uptake
Metastases	Multiple masses or nodules Pericardial effusion can be present Intense enhancement after contrast	T1: hypointense (hyperintense in melanoma metastases) T2: hyperintense	Perfusion: diffuse/heterogeneous LGE: heterogeneous	Hypodense with enhancement	High uptake

EGE = early gadolinium enhancement; LAA = left atrial appendage; LGE = late gadolinium enhancement; TIW fat-sat = T1-weighted fat saturation; other abbreviations as in Table 1.

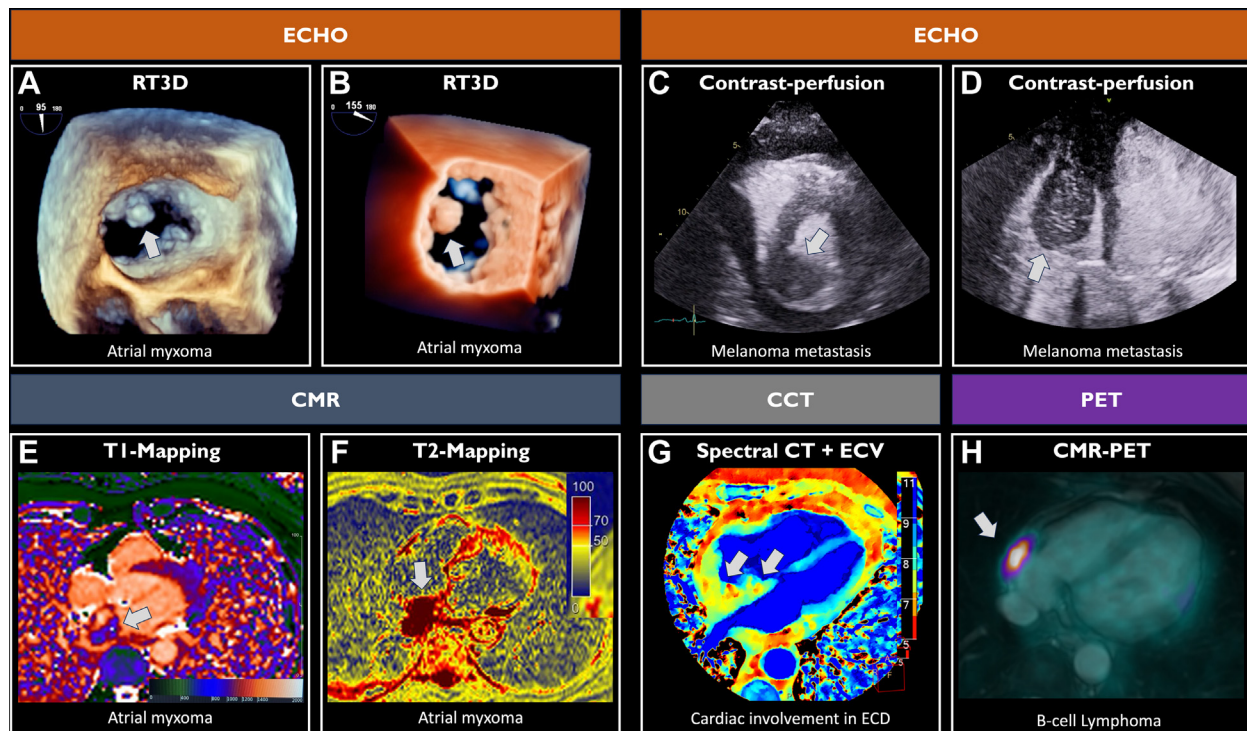
intraoperative guidance during surgical treatment of cardiac masses.²⁰ Additionally, contrast-enhanced echocardiography can help overcome limitations caused by poor acoustic windows and offers a preliminary assessment of cardiac mass vascularity (Figures 2C and 2D). This capability aids in determining the nature of the mass and ruling out cardiac thrombi, which are nonvascularized and do not show perfusion after the administration of ultrasound-enhancing agents.^{9,14}

TIPS AND TRICKS. TEE is considered the diagnostic gold standard for detecting small (<1 cm) and highly mobile lesions, such as vegetations, papillary

fibroelastomas, or masses involving the valves, because of its superior temporal resolution compared with cardiac magnetic resonance (CMR).²¹

For distinguishing between cardiac masses and pseudotumors, contrast-enhanced echocardiography can be useful, particularly when differentiating vascular tumors from cardiac thrombi.^{9,14}

At echocardiographic assessments, 6 red flags—infiltration, polylobate mass, significant pericardial effusion, sessile attachment, inhomogeneity, and non-left-sided localization—are key indicators of malignancy.^{15,16} Integrating these red flags into scoring systems, such as the diagnostic echocardiographic

FIGURE 2 Latest Advances in Multimodality Imaging for Cardiac Masses

(A,B) Atrial myxoma shown in real-time 3-dimensional echocardiography. (C) Melanoma metastasis in the posterior basal wall of the left ventricle, with mild contrast uptake observed on contrast echocardiography. (D) Right ventricle melanoma metastasis, with mild heterogeneous contrast uptake on contrast echocardiography. (E,F) Parametric mapping of a patient with an atrial myxoma, showing reduced T1 relaxation time (≈ 830 ms) and increased T2 relaxation time (≈ 130 ms). (G) Example of atrial involvement in Erdheim-Chester disease (ECD) on spectral CT. The cardiac mass shows a lower atomic number ("Z-effective" = 5-8) compared with the right and left myocardium ("Z-effective" = 8-11). (H) B-cell lymphoma localized in the atrium, seen with CMR-PET fusion imaging (SUVmax = 7). In this patient, both CMR and cardiac CT were inconclusive in characterizing the cardiac mass. The gray arrows indicate the cardiac mass. Echo = echocardiography; ECV = extracellular volume; RT3D = real-time 3-dimensional echocardiography; other abbreviations as in [Figure 1](#).

mass score, can significantly improve the diagnostic accuracy for identifying malignant cardiac masses. The diagnostic echocardiographic mass score, in particular, achieves approximately 90% diagnostic accuracy (area under the curve [AUC]: 0.965; 95% CI: 0.938-0.993; sensitivity 84%; specificity 96%).¹⁶

KEY MESSAGE. Echocardiography is typically the first noninvasive imaging test in patients with suspected cardiac masses and for follow-up monitoring. In addition to assessing overall cardiac function, key information, such as mass localization, morphology, and the presence of red flags suggestive of malignancy, should be thoroughly assessed and reported. In certain cases, TEE, contrast echocardiography, and RT3DE can provide additional value.

CMR

FOR WHOM AND WHEN. CMR plays a central role in the evaluation of cardiac masses and is considered

the gold standard after echocardiographic assessment. Indeed, except in specific cases, such as highly mobile valvular lesions, all patients with suspected cardiac masses should undergo a comprehensive CMR evaluation.^{12,22} When available, CMR may also be useful for follow-up in patients with cardiac masses, such as monitoring LV thrombus resolution or after surgical resection.

STRENGTHS AND WEAKNESSES. Compared with echocardiography, CMR has the unique advantage of providing tissue characterization with remarkable accuracy, often identifying cardiac mass malignancy with precision comparable with that of histology.^{12,21,23} In some cases, it can even provide a definitive diagnosis of cardiac mass histology, such as with lipomas or melanomas. Because of its high spatial resolution, CMR is superior in detecting infiltration or invasion of surrounding tissues, which is critical for preoperative surgical planning.^{9,24}

Additionally, in cases in which echocardiographic imaging is limited by a poor acoustic window, CMR becomes the primary technique for cardiac mass assessment.

However, some limitations should be noted. CMR requires electrocardiographic gating to avoid artifacts, and image quality can be compromised in the presence of arrhythmias or because of the long acquisition time (30 minutes to 1 hour).²⁵ In cases of arrhythmias, real-time cine sequences and single-shot late gadolinium enhancement (LGE) techniques may be useful. CMR is not suitable for patients with hemodynamic instability or older generation cardiac devices.²⁶ Claustrophobia, which may hinder the completion of the examination, can be managed with strategies such as premedication with anxiolytics or prone imaging. Regarding tissue characterization, T2-weighted images are susceptible to motion artifacts, slow flow, and signal intensity variability.²¹ Moreover, because of its lower temporal resolution compared with echocardiography, CMR is not indicated for evaluating valvular vegetations or small lesions (<1 cm).^{8,9,21}

WHAT TO LOOK FOR. CMR provides a comprehensive assessment of mass localization, morphology, hemodynamic effects, and tissue characterization using a standardized and widely applicable protocol.

Cine images, typically acquired with steady-state free precession sequences, allow the assessment of cardiac mass localization and morphologic features, both of which have important prognostic implications.⁶ Cardiac mass dimensions should be reported when possible, although it can be challenging with polylobate or infiltrative masses. Morphologic features raising suspicion for malignancy, which should not be overlooked during CMR analysis, include a diameter >5 cm, a polylobate appearance, a broad base of attachment (sessile), and irregular margins with infiltration into surrounding structures (Supplemental Figures 2A and 2B).²⁷ The presence and nature of pericardial effusion (hemorrhagic vs transudate or exudate) can also suggest malignancy, regardless of pericardiocentesis fluid analysis results. The hemodynamic effect of the cardiac mass, such as valve or outflow tract obstruction and/or impingement, can be assessed using cine steady-state free precession sequences, which may be complemented by phase-contrast sequences.²⁸

Precontrast tissue characterization is assessed using T1- and T2-weighted (short-tau inversion recovery) sequences and, more recently, parametric mapping techniques (Supplemental Figures 2C and 2D). T1- and T2-weighted fast spin echo imaging, with and without fat saturation (fat saturation, Dixon, or

spectral attenuated inversion recovery technique), helps determine whether a mass contains a high amount of fat or fluid. Cardiac masses with high signal intensity on T1-weighted images typically include fatty tumors (eg, lipomas, liposarcomas) and melanomas (due to melanin).

Conversely, masses that appear isointense or hypointense on T1-weighted sequences may indicate cysts, highly vascular tumors (eg, hemangiomas), or malignant masses, the latter of which exhibit hyperintensity on T2-weighted images. Cardiac myxomas typically present as isointense to hyperintense on T1-weighted images and hyperintense on T2-weighted sequences.²⁹ For thrombotic lesions, T1 and T2 values vary depending on the thrombus's age: 1) hyperintense on both T1- and T2-weighted sequences in the acute phase; 2) primarily hypertense on T1-weighted sequences with hypointense areas on T2-weighted sequences in the subacute phase; and 3) hypointense on both T1- and T2-weighted sequences in the chronic phase.³⁰ Cardiac metastases usually show low signal intensity on T1-weighted and high signal intensity on T2-weighted images.

Postcontrast tissue characterization in CMR follows a standard protocol including 3 key stages after contrast administration: 1) first-pass perfusion imaging, performed immediately after contrast administration; 2) early gadolinium enhancement, captured 1 to 3 minutes after contrast administration, with the inversion time set to null thrombus (approximately 500-550 ms at 1.5-T and 850-900 ms at 3-T)³¹; and 3) LGE, acquired 10 to 15 minutes after gadolinium injection.

First-pass perfusion imaging helps evaluate cardiac mass vascularization. Vascular tumors, such as hemangiomas and angiosarcomas, show early enhancement, and small vessels may be easily detectable. On first-pass sequences, necrotic areas, commonly found in malignant tumors, appear as black spots surrounded by contrast-enhancing tissue (Supplemental Figures 2E and 2F). Early gadolinium enhancement sequences are used to assess the thrombotic nature of cardiac masses, while LGE provides an accurate assessment of the extent of the extracellular compartment, which is directly related to vascularity, necrosis, and fibrosis.^{28,32} Malignancies typically show contrast enhancement on LGE, reflecting high tissue vascularity with focal areas of fibrosis or myocyte necrosis (Supplemental Figure 2H). Cardiac metastases typically display heterogeneous LGE patterns.³³ Conversely, benign tumors and cystic lesions generally do not exhibit contrast uptake, with the exception of myxomas and vascular lesions such as hemangiomas (Supplemental Figure 2G).³²

Overall, by providing a detailed and integrated assessment, CMR is able to distinguish between benign and malignant lesions with a diagnostic accuracy ranging from 92% to 100%.^{25,34,35}

LATEST ADVANCES. Recently, parametric mapping has been introduced and is now widely incorporated into the standard CMR protocols. This technique allows the direct quantification of relaxation times (T1, T2, and T2*) and the estimation of extracellular volume, further enhancing tissue characterization (**Figures 2E and 2F**).^{36,37} T2 mapping values may be increased in both malignant and benign tumors, particularly in myxomas, which are associated with increased T2 relaxation times.^{22,38} Additionally, perfusion CMR has recently been shown to yield prognostic information that complements LGE findings, with mortality increasing in proportion to the extent of lesion hypoperfusion.^{39,40}

TIPS AND TRICKS. Signal intensity in T1- and T2-weighted sequences alone is not sufficient to define the histotype of cardiac masses. For example, myxomas are hyperintense on T2-weighted sequences (**Supplemental Figure 2C**), similar to many malignant masses (**Supplemental Figure 2D**). However, certain T1- and T2-weighted signal patterns can be highly suggestive of specific histotypes. For instance, metastatic melanoma, a secondary tumor, exhibits a unique pattern with high T1-weighted signal intensity due to paramagnetic melanin.⁴¹ Lipomatous cardiac masses typically show homogeneous high signal intensity on T1-weighted sequences, slight hyperintensity on T2-weighted images, and hypointensity on fat-saturated images.³¹

Importantly, integrating morphologic with tissue characterization allows the identification of malignant masses with a diagnostic accuracy of 98.4% compared with histology.^{22,28} Additionally, the CMR mass score (range: 0-8; cutoff ≥ 5), which incorporates both mass morphology and tissue characterization, has shown superior accuracy compared with echocardiography in predicting the malignancy of cardiac masses, with significant prognostic implications (AUC: 0.976; 95% CI: 0.96-0.99).^{23,42}

Regarding the CMR acquisition protocol, it is recommended to include additional stacks in at least 2 orthogonal, customized imaging planes that optimally visualize the mass to enhance feature evaluation. In cases of unclear localization, cardiac masses can be evaluated by adding an axial stack of double inversion recovery static images, along with steady-state free precession static images for dark- and bright-blood imaging of the entire chest, adding only 2 to 3 minutes to the overall examination.

Alternatively, in complex cases, a preliminary cardiac computed tomography (CT) may be crucial for identifying the orthogonal imaging planes focused on the cardiac mass, as it precisely localizes the mass, its margins, and its relationship with surrounding structures with high spatial resolution. The information derived from cardiac CT can then guide a more focused CMR examination, improving the acquisition protocol and reducing the need for patient recall for further sequences. However, this approach should be reserved for complex cases with unclear localization, as it is not routine clinical practice.

KEY MESSAGE. CMR is the reference standard for noninvasive assessment of cardiac masses, except for small valvular masses and calcified lesions. It enables the accurate identification of pseudotumors, reducing the need for further testing, and allows the detection of malignant cardiac masses and, in some cases, specific histotypes.

CT

CT is a valuable imaging technique for evaluating cardiac masses, providing additional information that aids in both surgical and conservative patient management. When considering CT in the diagnostic work-up of patients with cardiac masses, it is important to differentiate between chest CT, which can be combined with abdominal and pelvic CT, and cardiac CT, as they have different acquisition protocols.

Although cardiac CT has less supporting evidence compared with CMR, it offers accurate tissue characterization, high spatial resolution, and a wide field of view, providing additional information on cardiac masses beyond what echocardiography provides.^{43,44} The role of CT in assessing cardiac masses has been increasingly recognized in recent guidelines and consensus documents in the field.^{12,43,44}

FOR WHOM AND WHEN. When used in combination with CMR, chest, abdominal, and pelvic (CAP) CT can help: 1) identify primary extracardiac malignancy; 2) define invasion or infiltration of surrounding extracardiac tissue; and 3) stage malignant lesions. Cardiac CT provides additional information in patients with calcified cardiac masses and those undergoing cardiac tumor resection. Specifically, it helps evaluate the anatomical relationships between the tumor and coronary arteries for surgical planning while also excluding obstructive coronary artery disease.⁴⁴ Moreover, cardiac CT is useful for evaluating and defining the nature of pericardial fluid, by measuring CT attenuation values in HU, and for assessing pericardial thickness and calcification in patients with suspected pericardial disease.⁴⁴

As an alternative to CMR, cardiac CT is the second-level imaging technique when CMR is contraindicated, such as patients with non-CMR-safe devices or claustrophobia, or when CMR is unavailable. However, it is important to note that the number of patients with non-CMR-safe devices has become extremely small in recent years, as CMR has been proved safe with virtually all devices. Similarly, the incidence of claustrophobia is very low and can often be managed with premedication (eg, anxiolytics) and prone imaging.⁴⁵ Nevertheless, cardiac CT offers the unique advantage of being a quicker test compared with CMR, which may be better tolerated by patients who struggle with repeated breath holds or prolonged supine positioning.⁴³ Moreover, cardiac CT is highly accurate in detecting and defining left atrial or left atrial appendage thrombi, small or calcified cardiac masses, and cardiac masses involving the great vessels.^{43,44}

STRENGTHS AND WEAKNESSES. The latest generation CT scanners combine high diagnostic accuracy with extremely fast image acquisition time, offering significantly more comfort for patients. Beyond defining surgical planes, cardiac CT enables the assessment of coronary artery anatomy, the relationship between cardiac masses and native coronary arteries (eg, proximity or invasion, such as the presence of the “tear-drop” sign⁴⁶), and coronary bypass grafts. It also evaluates the presence and severity of coronary artery disease, all of which are critical in choosing the best treatment strategy.⁹ Cardiac CT may also assist in preoperative planning.

When integrated with CAP CT, cardiac CT provides a comprehensive assessment of the cardiothoracic region, which is particularly useful for diagnosing involvement of surrounding organs and extracardiac findings (eg, lung cancer with cardiac involvement or pulmonary embolism). In case of metastases, CAP CT helps identify the primary tumor and stage the disease, especially when combined with ¹⁸F-fluorodeoxyglucose (¹⁸F-FDG) positron emission tomography (PET).⁴³

Moreover, CT plays a key role in guiding safe percutaneous biopsies and assessing the effects of antitumoral treatments.⁴⁶ However, disadvantages of CT include radiation exposure, risk for contrast-induced nephropathy or allergic reactions, and lower temporal resolution compared with CMR. Finally, although CAP CT can be combined with ¹⁸F-FDG PET, cardiac CT requires specific acquisition protocols.

WHAT TO LOOK FOR. Cardiac CT allows pre- and postcontrast image acquisition with submillimeter

(0.5 mm) spatial resolution using electrocardiographic gating, outperforming CMR in detecting small lesions.^{9,43} It provides detailed information on the location, size, and vascularity of cardiac masses, as well as their relationship with surrounding structures, vital information for surgical planning (Supplemental Figures 3A and 3B).

Cardiac CT also offers insight into the composition of cardiac masses, such as lipidic or calcific components, through both qualitative and semiquantitative assessments using HU. Pre- and postcontrast cardiac computed tomographic acquisition protocols require scanning across arterial, venous, and phase sequences. Precontrast images are particularly useful for detecting calcifications, which CMR cannot visualize^{34,46,47} (Supplemental Figures 3C to 3F). The postcontrast sequences allow the evaluation of the pattern and timing of cardiac mass enhancement, which can be particularly useful in characterizing vascular tumors (Supplemental Figures 3G and 3H).⁴³

Malignant tumors on cardiac CT are often distinguished by larger size, irregular margins, the presence of pericardial effusion, precontrast isodensity (compared with the myocardium), and contrast uptake (Supplemental Figures 3B, 3D, and 3H).⁴⁶

LATEST ADVANCES. Because of its high spatial resolution and 3-dimensional volumetric acquisition, cardiac CT enables the creation of 3-dimensional models of cardiac masses and surrounding structures, which aids in surgical planning.⁴⁸ Recent studies suggest that cardiac CT may also be useful for identifying and quantifying extracellular volume, which, when elevated, indicates fibrosis and inflammation (edema), with accuracy comparable with CMR.^{43,49} Thus, extracellular volume evaluation using cardiac CT could enhance tissue characterization of both the cardiac mass and surrounding structures, though further investigation is warranted.

In addition, the recently introduced photon-counting technology, with its unprecedented spatial resolution, holds promise for providing near-microscopic detail of cardiac masses.⁵⁰ Finally, spectral CT improves perfusion visualization, which can assist in the differential diagnosis between vascularized tumors and thrombotic lesions (Figure 2G).⁵¹

TIPS AND TRICKS. Cardiac CT is the diagnostic gold standard for identifying calcified masses. It is also valuable in distinguishing between intracavitary tumors and thrombi, with thrombi typically showing lower attenuation than the contiguous myocardium.⁵² A multiparametric assessment of 8 CT signs of cardiac mass—irregular margins, pericardial effusion, presence of calcification, invasion, dimension >3 cm,

solid component, isodense signal, and contrast enhancement—predicted malignancy with an AUC of 0.988 (95% CI: 0.97-0.99). Specifically, the presence of 5 or more of these computed tomographic signs accurately identifies malignancy (positive predictive value 100%), while the presence of fewer than 2 signs excludes it (negative predictive value 100%).⁴⁶ In cases in which 3 to 4 parameters are present—the grey zone—predictive yield was enhanced by positron emission tomographic evaluation.⁴⁶ However, it should be noted that the study did not aim to demonstrate the superiority of CT and PET/CT over CMR.

KEY MESSAGE. CT can be performed either in combination with or as an alternative to CMR. Cardiac CT is pivotal in presurgical scheduling, helping identify surgical planes, tailor surgical resection, and rule out coronary artery disease. CAP CT is typically used to identify primary extracardiac malignancies, define of invasion or infiltration of surrounding extracardiac tissues, and stage malignant lesions.

PET

FOR WHOM AND WHEN. ¹⁸F-FDG PET is recommended for differentiating malignancy when cardiac computed tomographic or CMR results are inconclusive.^{9,46} It is also used for staging primary malignant tumors and detecting the primary tumor cases of cardiac metastases.

STRENGTHS AND WEAKNESSES. PET/CT offers high sensitivity but suboptimal specificity in identifying malignancy in cardiac masses. Benign tumors, such as myxomas and hemangiomas, can exhibit high metabolic activity, often resulting in significant ¹⁸F-FDG uptake.⁹ In addition, ¹⁸F-FDG PET/CT has poor specificity in cases of inflammation, particularly in infectious diseases, which may be misinterpreted as neoplastic because of high metabolic activity. Other disadvantages include notable radiation exposure and physiological myocardial uptake of ¹⁸F-FDG, which can obscure the visualization of mass metabolism. The quality of the study depends heavily on the dietary regimen prior to the scan, making it crucial to follow an appropriate high-fat, low-carbohydrate diet with prolonged fasting, as recommended by expert consensus guidelines.⁵³ Improper dietary preparation can result in missed detection of intramyocardial masses. In certain cases, PET may be superior in detecting intramyocardial masses with strong ¹⁸F-FDG avidity.

WHAT TO LOOK FOR. ¹⁸F-FDG PET provides a precise measurement of mass metabolic activity,^{12,54} which is

quantified by the maximum standardized uptake value (SUVmax).⁵⁵ Malignant tumors typically have higher SUVmax values than benign masses (Supplemental Figures 4A and 4B). However, certain benign tumors, such as myxomas and hemangiomas, along with infectious and inflammatory diseases, such as vegetations and cardiac sarcoidosis, can also exhibit high metabolic activity with significant ¹⁸F-FDG uptake.⁹ ¹⁸F-FDG PET is a powerful tool for ruling out malignancy, offering the best sensitivity when the mass shows no radiotracer uptake.

LATEST ADVANCES. ¹⁸F-FDG PET can be combined with CMR in hybrid imaging systems, such as ¹⁸F-FDG PET/magnetic resonance, which exposes patients to less radiation while providing improved tissue and morphologic characterization compared with ¹⁸F-FDG PET/CT or CMR alone. This combination reduces the rate of false-positive results (Figure 2H).^{28,40,56} However, its application remains limited to select cases because of limited availability and high costs.⁵⁶

Advances have also been made in positron emission tomographic imaging agents, with the introduction of tumor-specific tracers, though their application remains mostly in the research phase. Among these, fibroblast activation protein inhibitors and atezolizumab, which identifies PD-L1 expression levels, show great promise for detecting primary and metastatic disease. Additionally, benzamine tracers are melanoma specific and may aid in detecting melanoma metastases, staging, and therapy response. $\alpha_v\beta_3$ integrin can detect multiple tumor histotypes by visualizing neovascularization and infiltrating tumors.⁵⁷

TIPS AND TRICKS. Certain ¹⁸F-FDG PET parameters, such as metabolic tumor volume—which includes all spatially connected voxels within a fixed threshold of 40% of SUVmax—and total lesion glycolysis, the product of metabolic tumor volume and mean standardized uptake value, provide additional information, especially when cardiac CT yields inconclusive results.⁴⁶ To enhance the metabolism of cardiac masses relative to myocardial cells, adequate dietary preparation with high fat intake at least 12 hours before the examination is recommended. This dietary shift allows myocardial cells to switch to lipid metabolism, improving the visualization of neoplastic glucose-based metabolism.⁴⁶

In cases in which malignancies do not rely on glucose metabolism (such as neuroendocrine tumors), radiotracers such as ⁶⁸Ga-DOTATATE and ¹⁸F-fluorodihydroxyphenylalanine, which are available in clinical practice, should be used for detection.⁵⁸

KEY MESSAGE. ^{18}F -FDG PET is recommended as a third-level imaging technique when computed tomographic and CMR results are inconclusive. After evaluating the metabolic activity of the mass, systemic staging of malignant cardiac masses should be performed (Supplemental Figures 4C and 4D).

HISTOLOGIC DIAGNOSIS: ROLE OF CARDIAC BIOPSY

Biopsy has traditionally been regarded as the diagnostic gold standard, as histology provides critical information for treatment and prognosis, which depend largely on the tumor histotype. However, its routine use in clinical practice is limited because of its invasiveness (with associated procedural risks), the need for operator expertise, and costs.⁵⁹ Biopsy is indicated primarily for right-sided cardiac masses with an infiltrative or obstructive pattern and in the differential diagnosis of sarcomas, lymphomas, and metastatic tumors.⁶⁰ Although left-sided biopsy is possible, it is sometimes avoided because of the risk for systemic embolism.

False-negative results may occur because of sampling errors, reducing the biopsy sensitivity, but these errors can be minimized with imaging guidance. Imaging also helps reduce the risk for perforations by precisely localizing cardiac structures.⁶¹

PRACTICAL APPROACH TO USING MULTIMODALITY IMAGING

In clinical practice, multimodality imaging plays a crucial role in managing cardiac masses by addressing several key diagnostic objectives: 1) detecting and localizing cardiac mass; 2) identifying anatomical variants; 3) differentiating between cardiac tumors and pseudotumors; 4) detecting malignancy in cardiac tumors; 5) staging and guiding treatment; 6) presurgical planning; and 7) aiding in the determination of histology. Figure 3 presents an overview of the accuracy of each modality in fulfilling these diagnostic tasks during the work-up of patients with cardiac masses. Clinical presentations vary widely, ranging from incidental findings in asymptomatic patients to common cardiovascular or systemic signs and symptoms.

Echocardiography is typically the initial imaging approach for detecting and localizing cardiac masses. However, depending on the mass's location, echocardiography may not provide precise localization, necessitating additional imaging with CMR and/or CT for improved accuracy.

Echocardiography is generally reliable in identifying cardiac masses and excluding most anatomical variants. In cases in which uncertainty remains or

acoustic windows are suboptimal, CMR provides excellent diagnostic performance for ruling out anatomical variants.

When considering the differential diagnosis between cardiac tumors and pseudotumors, integrating echocardiography and CMR is typically the most accurate and cost-effective choice. However, in cases involving calcific cardiac masses, cardiac CT is preferred because of its superior ability to visualize calcifications. For identifying malignancy in cardiac tumors, whether benign or malignant, CMR (alone or combined with CT), cardiac CT, and/or PET provide the highest diagnostic accuracy. It is important to look for red flags of malignancy during any noninvasive imaging test, and these findings should be integrated into a multiparametric score to improve the predictive accuracy.

Staging and treatment guidance for malignant tumors are usually performed using CAP CT in combination with PET. CT, in combination with CMR, plays a pivotal role in presurgical planning. For defining histology, biopsy remains the gold standard.

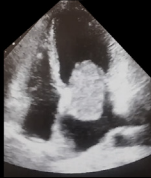
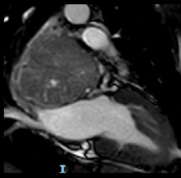
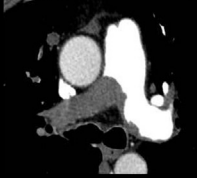


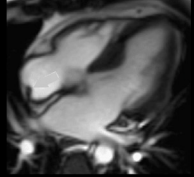
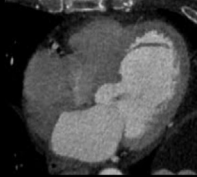

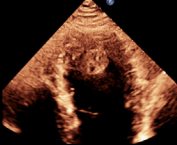
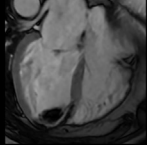
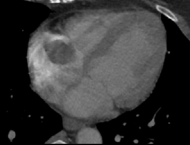
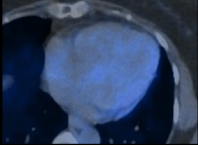
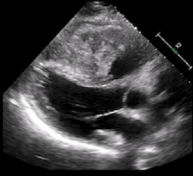
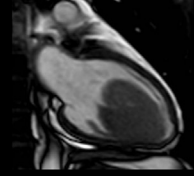
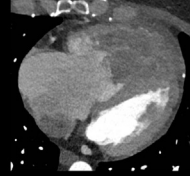
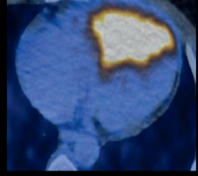
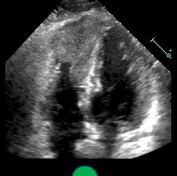
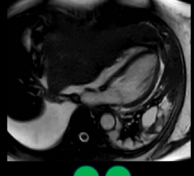
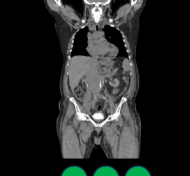
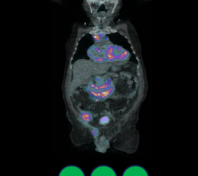
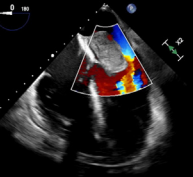
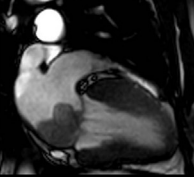
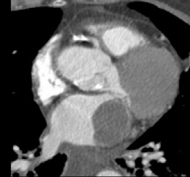
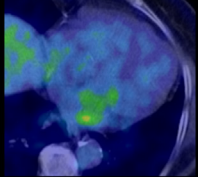
Two diagnostic scenarios for patients with suspected benign or malignant cardiac masses are described in the Supplemental Appendix and the Central Illustration.

FUTURE DIRECTIONS

Radiomics, an application of artificial intelligence, focuses on extracting quantitative data from radiographic images that are not visually apparent and using these data to create clinical decision support systems. This approach enables highly accurate predictions by analyzing high-dimensional, multimodal data. Radiomics also uses machine learning, a subset of artificial intelligence, which allows machines to perform intelligent tasks and improve through experience. Over the past decade, several studies have highlighted the potential of radiomics in oncology, particularly for coronary computed tomographic angiography and CMR.^{62,63} However, there are currently no data specific to cardiac masses. Applying radiomics to cardiac masses could optimize detection, tissue characterization, and monitoring of the response to treatment, ultimately improving patient management and prognosis. In the diverse clinical setting of cardiac masses, artificial intelligence algorithms could bridge the gap between morphologically similar cases with different prognoses, making radiomics a valuable complementary tool for multimodality imaging.

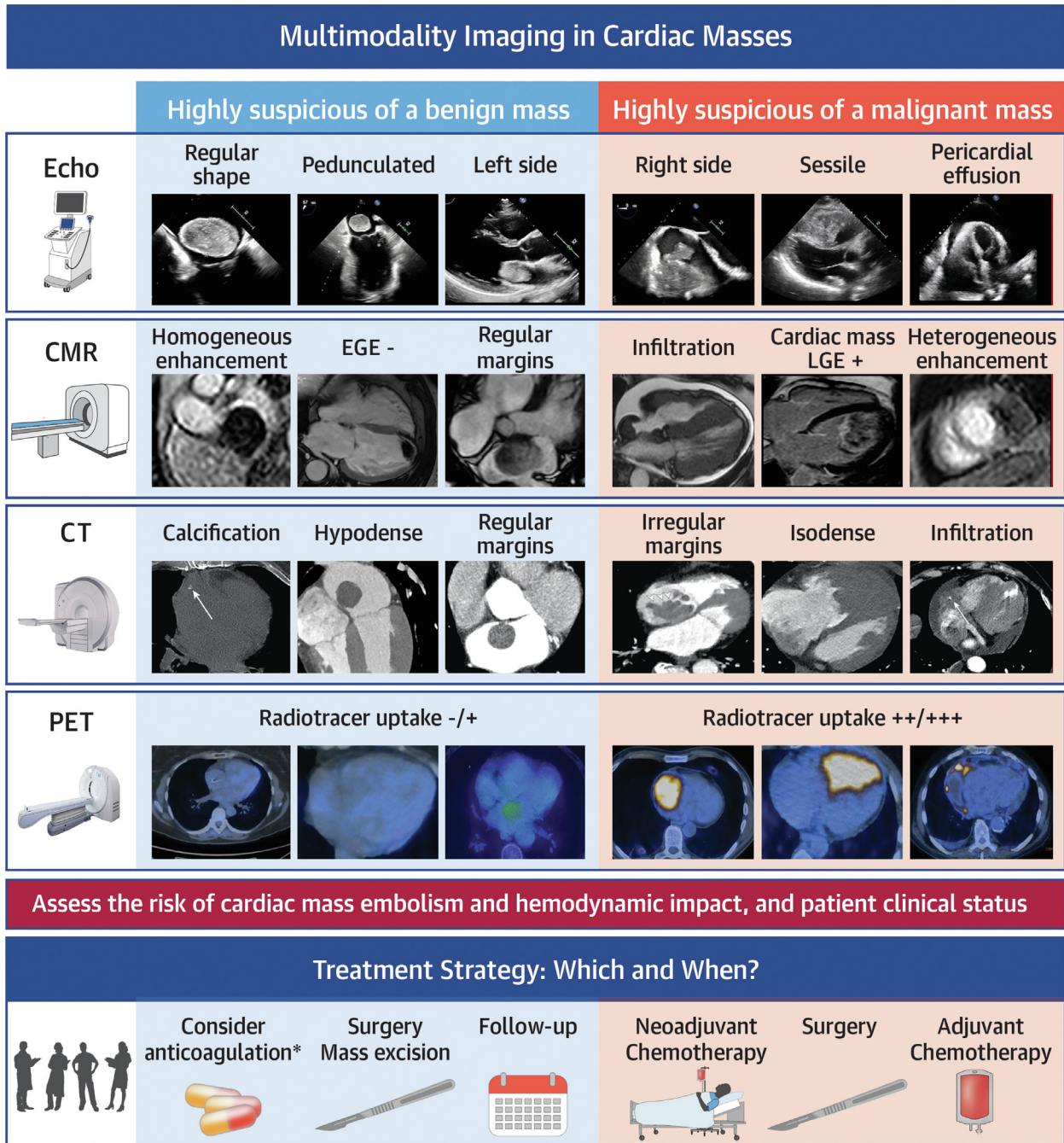
Recent technological advancements in noninvasive imaging have facilitated the use of stereotactic

FIGURE 3 Diagnostic Accuracy of Multimodality Imaging in Characterizing Cardiac Masses

	ECHO	CMR	CT	PET
Detection and localization	 ● ● ●	 ● ● ●	 ● ● ●	
Identification of anatomical variants	 ● ● ●	 ● ● ●	 ● ●	
Differentiate tumors from pseudotumors	 ● ●	 ● ● ●	 ● ● ●	 ●
Detection of malignancy	 ● ●	 ● ● ●	 ● ● ●	 ● ● ●
Staging and guidance of treatment	 ●	 ● ●	 ● ● ●	 ● ● ●
Pre-surgical planning	 ●	 ● ●	 ● ● ●	 ● ●

The ability of various imaging modalities to detect and localize cardiac masses, differentiate them from anatomical variants and pseudotumors, predict malignancy, assist with staging and treatment planning, and guide presurgical planning is depicted. Green circles indicate where the technique is useful in clinical cases, while red crosses highlight aspects for which that imaging method is less effective. Abbreviations as in Figure 1.

CENTRAL ILLUSTRATION Red Flags for Malignancy in Cardiac Masses Identified Through Multimodality Imaging



Angeli F, et al. JACC CardioOncol. 2024;■(■):■-■.

This illustration summarizes key imaging findings across different modalities, highlighting 2 diagnostic scenarios for patients with suspected benign or malignant cardiac masses. *When clinically indicated. CMR = cardiac magnetic resonance; CT = computed tomography; EGE = early gadolinium enhancement; Echo = echocardiography; LGE = late gadolinium enhancement; PET = positron emission tomography.

body radiotherapy for cardiac targets, including tumors. A new technique, echocardiography-guided transapical radiofrequency ablation for cardiac tumors, has been proposed as a debulking therapy for patients with cardiac tumors who are unsuitable for or unable to tolerate surgical resection, chemotherapy, or definitive or palliative radiation therapy, as determined by a multidisciplinary team. Preliminary data indicate that this procedure effectively reduces the size of cardiac tumors, improves hemodynamic status, and alleviates clinical symptoms.²⁰

CONCLUSIONS

The noninvasive diagnosis of cardiac masses is rapidly evolving, with numerous imaging modalities now readily available and new technologies continually emerging. Echocardiography remains the initial test for patients with suspected cardiac masses, although the first detection of a cardiac mass can occur through any noninvasive modality, often as an incidental finding. CMR is considered the gold standard for comprehensive evaluation and tissue characterization, while CT, either in combination with or as an alternative to CMR, plays a critical role in specific cases and presurgical planning. When results are inconclusive, ¹⁸F-FDG PET is invaluable for identifying cardiac mass malignancy and assisting in staging malignant tumors.

In practice, the diagnostic approach is often influenced by the availability of local resources and

expertise. It is important to raise awareness of the significant benefits multimodality imaging offers, particularly in more complex cases. However, this does not imply that every patient with a cardiac mass should undergo all available noninvasive techniques. Clinicians must understand the strengths and weaknesses of each modality to select the most appropriate and cost-effective combination tailored to the patient's need.

Additionally, recognizing the potential of multimodality imaging helps clinicians identify when to refer patients to third-level centers if local resources are limited. A multidisciplinary team approach ensures the optimal use of multimodality imaging and helps provide the best care for patients with cardiac masses.

FUNDING SUPPORT AND AUTHOR DISCLOSURES

The authors have reported that they have no relationships relevant to the contents of this paper to disclose.

ADDRESS FOR CORRESPONDENCE: Dr Carmine Pizzi, Cardiology Unit, Cardiac Thoracic and Vascular Department, IRCCS Azienda Ospedaliera-Universitaria di Bologna, Department of Medical and Surgical Sciences, DIMEC Alma Mater Studiorum, University of Bologna, Via Massarenti, 9, 40138 Bologna, Italy. E-mail: carmine.pizzi@unibo.it. X handle: [@pizzi_carmine](https://twitter.com/pizzi_carmine).

REFERENCES

- Burke A, Tavora F. The 2015 WHO classification of tumors of the heart and pericardium. *J Thorac Oncol*. 2016;11:441-452.
- Butany J, Nair V, Naseemuddin A, Nair GM, Catton C, Yau T. Cardiac tumours: diagnosis and management. *Lancet Oncol*. 2005;6:219-228.
- Habertheuer A, Laufer G, Wiedemann D, et al. Primary cardiac tumors on the verge of oblivion: a European experience over 15 years. *J Cardiothorac Surg*. 2015;10:56.
- Elbardissi AW, Dearani JA, Daly RC, et al. Survival after resection of primary cardiac tumors: a 48-year experience. *Circulation*. 2008;118:57-515.
- Sultan I, Bianco V, Habertheuer A, et al. Long-term outcomes of primary cardiac malignancies: multi-institutional results from the National Cancer Database. *J Am Coll Cardiol*. 2020;75:2338-2347.
- Foà A, Paolisso P, Bergamaschi L, et al. Clues and pitfalls in the diagnostic approach to cardiac masses: are pseudo-tumours truly benign? *Eur J Prev Cardiol*. 2022;29:e102-e104.
- Angeli F, Bergamaschi L, Paolisso P, et al. Spectrum of ECG abnormalities in a large cohort of cardiac masses. *Heart Rhythm*. Published online June 21, 2024. <https://doi.org/10.1016/j.hrthm.2024.06.035>
- Angeli F, Fabrizio M, Paolisso P, et al. [Cardiac masses: classification, clinical features and diagnostic approach]. *G Ital Cardiol (Rome)*. 2022;23:620-630.
- Tyebally S, Chen D, Bhattacharyya S, et al. Cardiac tumors. *JACC CardioOncol*. 2020;2:293-311.
- Wu CM, Bergquist PJ, Srichai MB. Multimodality imaging in the evaluation of intracardiac masses. *Curr Treat Options Cardiovasc Med*. 2019;21:55.
- Lemaste M, Lavie Badie Y, Cariou E, et al. Contribution and performance of multimodal imaging in the diagnosis and management of cardiac masses. *Int J Cardiovasc Imaging*. 2020;36:971-981.
- Lyon AR, López-Fernández T, Couch LS, et al. 2022 ESC guidelines on cardio-oncology developed in collaboration with the European Hematology Association (EHA), the European Society for Therapeutic Radiology and Oncology (ESTRO
- and the International Cardio-Oncology Society (IC-OS). *Eur Heart J*. 2022;43:4229-4361.
- Angeli F, Bergamaschi L, Rinaldi A, et al. Sex-related disparities in cardiac masses: clinical features and outcomes. *J Clin Med*. 2023;12:2958.
- Siebelink H-MJ, Scholte AJHA, Van de Veire NR, et al. Value of contrast echocardiography for left ventricular thrombus detection post-infarction and impact on antithrombotic therapy. *Coron Artery Dis*. 2009;20:462-466.
- Paolisso P, Foà A, Bergamaschi L, et al. Echocardiographic markers in the diagnosis of cardiac masses. *J Am Soc Echocardiogr*. 2023;36(5):464-473.e2.
- Paolisso P, Foà A, Magnani I, et al. Development and validation of a diagnostic echocardiographic mass score in the approach to cardiac masses. *JACC Cardiovasc Imaging*. 2022;15:2010-2012.
- Lestuzzi C, Biasi S, Nicolosi GL, et al. Secondary neoplastic infiltration of the myocardium diagnosed by two-dimensional echocardiography in seven cases with anatomic confirmation. *J Am Coll Cardiol*. 1987;9:439-445.

18. Islam AKMM. Cardiac myxomas: a narrative review. *World J Cardiol.* 2022;14:206-219.
19. Zaragoza-Macias E, Chen MA, Gill EA. Real time three-dimensional echocardiography evaluation of intracardiac masses. *Echocardiography.* 2012;29(2):207-219.
20. Huang J, Lei C, Hsi DH, et al. Echocardiography-guided radiofrequency ablation for cardiac tumors. *JACC CardioOncol.* 2024;6(4):560-571.
21. Fussen S, De Boeck BWL, Zellweger MJ, et al. Cardiovascular magnetic resonance imaging for diagnosis and clinical management of suspected cardiac masses and tumours. *Eur Heart J.* 2011;32:1551-1560.
22. Shenoy C, Grizzard JD, Shah DJ, et al. Cardiovascular magnetic resonance imaging in suspected cardiac tumour: a multicenter outcomes study. *Eur Heart J.* 2021;43:71-80.
23. Paolisso P, Bergamaschi L, Angeli F, et al. Cardiac magnetic resonance to predict cardiac mass malignancy: the CMR mass score. *Circ Cardiovasc Imaging.* 2024;17:e016115.
24. Li X, Chen Y, Liu J, et al. Cardiac magnetic resonance imaging of primary cardiac tumors. *Quant Imaging Med Surg.* 2020;10:294-313.
25. Semelka RC, Shoenut JP, Wilson ME, Pellech AE, Patton JN. Cardiac masses: signal intensity features on spin-echo, gradient-echo, gadolinium-enhanced spin-echo, and TurboFLASH images. *J Magn Reson Imaging.* 1992;2:415-420.
26. Zhu D, Yin S, Cheng W, et al. Cardiac MRI-based multi-modality imaging in clinical decision-making: preliminary assessment of a management algorithm for patients with suspected cardiac mass. *Int J Cardiol.* 2016;203:474-481.
27. Parwani P, Co M, Ramesh T, et al. Differentiation of cardiac masses by cardiac magnetic resonance imaging. *Curr Cardiovasc Imaging Rep.* 2020;13:1.
28. Gatti M, D'Angelo T, Muscogiuri G, et al. Cardiovascular magnetic resonance of cardiac tumors and masses. *World J Cardiol.* 2021;13:628-649.
29. Abbas A, Garfath-Cox KaG, Brown IW, Shambrook JS, Peebles CR, Harden SP. Cardiac MR assessment of cardiac myxomas. *Br J Radiol.* 2015;88:20140599.
30. Rueff LE, Srichai MB, Jacobs JE, Axel L, Lim RP. CT and MRI appearances of cardiac pseudotumours. *J Med Imaging Radiat Oncol.* 2013;57:582-588.
31. Bonnes J, Brink M, Nijveldt R. How to evaluate cardiac masses by cardiovascular magnetic resonance parametric mapping? *Eur Heart J Cardiovasc Imaging.* 2023;24:1605-1607.
32. Pennell DJ, Sechtem UP, Higgins CB, et al. Clinical indications for cardiovascular magnetic resonance (CMR): consensus panel report. *Eur Heart J.* 2004;25:1940-1965.
33. Pun SC, Plodkowski A, Matasar MJ, et al. Pattern and prognostic implications of cardiac metastases among patients with advanced systemic cancer assessed with cardiac magnetic resonance imaging. *J Am Heart Assoc.* 2016;5:e003368.
34. Hoey ETD, Mankad K, Puppala S, Gopalan D, Sivananthan MU. MRI and CT appearances of cardiac tumours in adults. *Clin Radiol.* 2009;64:1214-1230.
35. Kassi M, Polsani V, Schutt RC, et al. Differentiating benign from malignant cardiac tumors with cardiac magnetic resonance imaging. *J Thorac Cardiovasc Surg.* 2019;157:1912-1922.
36. White SK, Sado DM, Fontana M, et al. T1 mapping for myocardial extracellular volume measurement by CMR: bolus only versus primed infusion technique. *JACC Cardiovasc Imaging.* 2013;6:955-962.
37. Spieker M, Haberkorn S, Gastl M, et al. Abnormal T2 mapping cardiovascular magnetic resonance correlates with adverse clinical outcome in patients with suspected acute myocarditis. *J Cardiovasc Magn Reson.* 2017;19:38.
38. Yue P, Xu Z, Wan K, et al. Multiparametric mapping by cardiovascular magnetic resonance imaging in cardiac tumors. *J Cardiovasc Magn Reson.* 2023;25:37.
39. Chan AT, Maya TR, Park C, et al. Incremental utility of first-pass perfusion CMR for prognostic risk stratification of cancer-associated cardiac masses. *JACC Cardiovasc Imaging.* 2024;17:128-145.
40. Chan AT, Fox J, Perez Johnston R, et al. Late gadolinium enhancement cardiac magnetic resonance tissue characterization for cancer-associated cardiac masses: metabolic and prognostic manifestations in relation to whole-body positron emission tomography. *J Am Heart Assoc.* 2019;8:e011709.
41. Enochs WS, Petherick P, Bogdanova A, Mohr U, Weissleder R. Paramagnetic metal scavenging by melanin: MR imaging. *Radiology.* 1997;204:417-423.
42. Hoit BD. Benign or malignant cardiac mass: refining the role of cardiac magnetic resonance. *Circ Cardiovasc Imaging.* 2024;17:e016574.
43. Lopez-Mattei JC, Yang EH, Ferencik M, Baldassarre LA, Dent S, Budoff MJ. Cardiac computed tomography in cardio-oncology: JACC: CardioOncology primer. *JACC CardioOncol.* 2021;3:635-649.
44. Lopez-Mattei J, Yang EH, Baldassarre LA, et al. Cardiac computed tomographic imaging in cardio-oncology: an expert consensus document of the Society of Cardiovascular Computed Tomography (SCCT). Endorsed by the International Cardio-Oncology Society (ICOS). *J Cardiovasc Comput Tomogr.* 2023;17:66-83.
45. Hudson DM, Heales C, Meertens R. Review of claustrophobia incidence in MRI: a service evaluation of current rates across a multi-centre service. *Radiography (Lond).* 2022;28:780-787.
46. D'Angelo EC, Paolisso P, Vitale G, et al. Diagnostic accuracy of cardiac computed tomography and 18-F fluorodeoxyglucose positron emission tomography in cardiac masses. *JACC Cardiovasc Imaging.* 2020;13:2400-2411.
47. Kassop D, Donovan MS, Cheezum MK, et al. Cardiac masses on cardiac CT: a review. *Curr Cardiovasc Imaging Rep.* 2014;7:9281.
48. Al Jabbari O, Abu Saleh WK, Patel AP, Igo SR, Reardon MJ. Use of three-dimensional models to assist in the resection of malignant cardiac tumors. *J Card Surg.* 2016;31:581-583.
49. Han D, Lin A, Kuronuma K, et al. Cardiac computed tomography for quantification of myocardial extracellular volume fraction: a systematic review and meta-analysis. *JACC Cardiovasc Imaging.* 2023;16:1306-1317.
50. Bie J van der, Straten M van, Booiij R, et al. Photon-counting CT: review of initial clinical results. *Eur J Radiol.* 2023;163:110829.
51. Hong YJ, Hur J, Han K, et al. Quantitative analysis of a whole cardiac mass using dual-energy computed tomography: comparison with conventional computed tomography and magnetic resonance imaging. *Sci Rep.* 2018;8:15334.
52. Goldstein JA, Schiller NB, Lipton MJ, Ports TA, Brundage BH. Evaluation of left ventricular thrombi by contrast-enhanced computed tomography and two-dimensional echocardiography. *Am J Cardiol.* 1986;57:757-760.
53. Chareonthaitawee P, Beanlands RS, Chen W, et al. Joint SNMMI-ASNC expert consensus document on the role of ¹⁸F-FDG PET/CT in cardiac sarcoid detection and therapy monitoring. *J Nucl Med.* 2017;58:1341-1353.
54. Saponara M, Ambrosini V, Nannini M, et al. ¹⁸F-FDG-PET/CT imaging in cardiac tumors: illustrative clinical cases and review of the literature. *Ther Adv Med Oncol.* 2018;10:1758835918793569.
55. Rahbar K, Seifarth H, Schäfers M, et al. Differentiation of malignant and benign cardiac tumors using ¹⁸F-FDG PET/CT. *J Nucl Med.* 2012;53:856-863.
56. Nensa F, Tezghah E, Poeppel TD, et al. Integrated ¹⁸F-FDG PET/MR imaging in the assessment of cardiac masses: a pilot study. *J Nucl Med.* 2015;56(2):255-260.
57. Vercellino L, Jong D de, Dercle L, et al. Translating molecules into imaging—the development of new PET tracers for patients with melanoma. *Diagn Basel Switz.* 2022;12:1116.
58. Liu M, Armeni E, Navalkisoor S, et al. Cardiac metastases in patients with neuroendocrine tumours: clinical features, therapy outcomes, and prognostic implications. *Neuroendocrinology.* 2021;111:907-924.
59. Bermpis K, Esposito G, Gallinoro E, et al. Safety of right and left ventricular endomyocardial biopsy in heart transplantation and cardiomyopathy patients. *JACC Heart Fail.* 2022;10:963-973.
60. Leone O, Veinot JP, Angelini A, et al. 2011 consensus statement on endomyocardial biopsy from the Association for European Cardiovascular Pathology and the Society for Cardiovascular Pathology. *Cardiovasc Pathol.* 2012;21:245-274.

61. Zanobini M, Dello Russo A, Saccocci M, et al. Endomyocardial biopsy guided by intracardiac echocardiography as a key step in intracardiac mass diagnosis. *BMC Cardiovasc Disord.* 2018;18:15.

62. Haneberg AG, Pierre K, Winter-Reinhold E, et al. Introduction to radiomics and artificial intelligence: a primer for radiologists. *Semin Roentgenol.* 2023;58:152-157.

63. Madan N, Lucas J, Akhter N, et al. Artificial intelligence and imaging: opportunities in cardiology. *Am Heart J Plus Cardiol Res Pract.* 2022;15:100126.

KEY WORDS cardiac computed tomography, cardiac magnetic resonance, cardiac mass, echocardiography,

multimodality imaging, positron emission tomography

APPENDIX For diagnostic scenarios for suspicion of benign and malignant masses, supplemental references, and figures, please see the online version of this paper.